

# Tendinoraphy in the Foot Utilizing Concentrated Autologous Platelet Grafting: TWO CASE STUDIES

By: Dr. Howard L. Schultheiss Jr., DPM

Fellow, American Professional Wound Care Association

Diplomat, American Council of Certified Podiatric Physicians and Surgeons

## INTRODUCTION

Concentrated platelets from the patient's own blood, as a grafting material, has been successfully used in orthopedic surgery, maxillofacial surgery and in the wound care arena for the past several years. (123) Recently, autologous platelet grafting (APG), utilizing Platelet Rich Plasma, (PRP) has been used in the podiatric arena for the treatment of chronic plantar fasciitis. (4) In almost all cases, PRP is applied to the area in need and cellular degranulation of the concentrated platelets results in the desired effect. A brief discussion of APG will be followed by the presentation of two case studies, partial rupture of an Achilles tendon and a tibialis anterior tendon, which were unresponsive to conservative care and resolved with the injection of APG.

## DISCUSSION

Initially made the decision to augment my practice with the availability of PRP and autologous platelet grafting to enhance the level of delivery of wound care. To treat chronic wounds, concentrated platelets are mixed in a 10:1 ratio with thrombin to activate the fibrin and form a clot of PRP which is used on a prepared wound bed. Degranulation of the platelets results in delivery of growth factors to the wound bed, enhancing healing. (1) Growth Factors released include; platelet derived growth factor, platelet derived angiogenesis factor, transforming growth factor- $\beta$ , insulin-like growth factor, and platelet derived endothelial cell growth factor. (2) These factors work together to enhance the wound bed environment and stimulate healing. In his monograph, (3) Almekinders discussed a biological approach to treatment of soft tissue in chronic tendonitis, which he preferred to refer to as tendinopathy. He explained that the injured tendon was stuck in a chronic inflammatory state, which is similar to a chronic non-healing ulcer. This was also found to be true by Barrett in the treatment of chronic plantar fasciitis where he utilized growth factors from Platelet Rich Plasma (PRP) for his treatment. (4) Animal models were used to show enhanced healing of ruptured Achilles tendons when PRP is applied to the injured sight. (5) Another study in the orthopedic literature supports the use of PRP for soft tissue healing in chronic lateral epicondylitis. (6) PRP has also been found to be beneficial in enhancing bone healing. (7) In the following two cases autologous PRP is applied as a graft, under direct ultrasound

visualization, to the defect of a chronic tendon rupture. This is similar in method as described by Barrett to treat plantar fasciitis. In both of the cases, complete resolution of symptoms occurred as well as repair of the tendon as demonstrated by ultrasound.

## CASE 1

A 45 y.o. female letter carrier presented with a chief concern of sudden onset of aching pain, five weeks in duration, on the anteriomedial aspect of the right ankle that occurred while exercising. Her PMH is positive for depression, back pain, hyperlipidemia and hypothyroid. She rested the part and took NSAID's without improvement. She suffered limitation of her activities as the pain progressed which prompted the visit. Palpation of the tibialis anterior tendon at the level of the ankle revealed significant pain. Partial rupture of the tendon was confirmed with ultrasound. She was treated with six weeks of immobilization with a pneumatic walking cast. With no improvement in her condition, the risks, benefits and possible complications of APG with PRP was discussed with the patient. The patient underwent the procedure without complications. When she returned for her first postoperative visit at one week, she noted vast improvement of symptoms, with resolution of aching pain, reduced to a dull soreness. At two weeks she was able to walk short distances without the pneumatic walking cast, displayed minimal tenderness, and the ultrasound displayed resolution of the rupture. At one month post-op she was released to light duty with a multi-ligamentous ankle brace. At two months she was released from my care with complete resolution of symptoms and ultrasound confirmation of tendon repair.

## CASE 2

A 53 y.o. female with a history of carpal tunnel syndrome, obesity and arthritis presented with a chief concern of sudden onset of pain and swelling on the posterior aspect of the left heel. Diagnostic ultrasound revealed that she suffered an acute partial rupture of the Achilles tendon at it's insertion on the calcaneous. She was started on naprosyn and immobilization in a pneumatic walking cast for six weeks. Upon her return she continued to have a palpable defect and recoiled in pain when the ruptured sight was palpated. Her pain was at a level 10. Achillies tendinoraphy using PRP was performed. She underwent surgery without complications. The patient stated that she had a 50% improvement

## CASE 1

Fig. 1

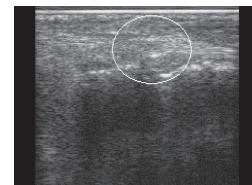
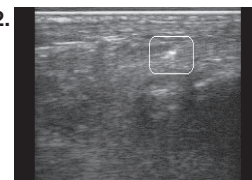


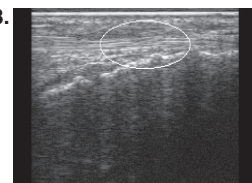
Image displaying the tibialis anterior tendon rupture.

Fig. 2.



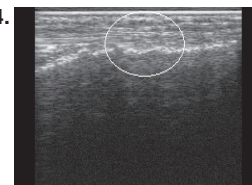
Intraoperative image of needle in substance of the tibialis anterior tendon.

Fig. 3.



One month post op with approximately 80% complete tendon repair. Clinically the patient is almost completely pain free.

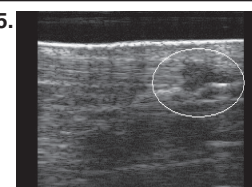
Fig. 4.



Week six with complete tendon repair, tibialis anterior.

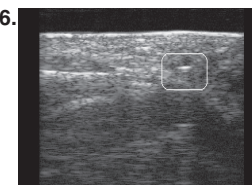
## CASE 2

Fig. 5.



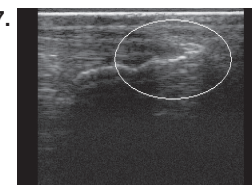
Rupture of Achilles tendon.

Fig. 6.



Intraoperative image with insertion of needle in defect.

Fig. 7.



Six weeks postoperative with complete tendon healing.

in her pain, and diagnostic ultrasound revealed between 25 and 50% re-growth of tendinous structure. At two weeks the pain was reduced to a "2", and there was 80% tendinous re-growth. At one month the patient was painfree, and there was 100% regrowth. The patient went on to suffer with another unrelated foot problem after her release, but this was not associated to the Achilles tendon, which remained pain free.

## **MATERIALS AND METHODS**

The patient receives oral sedation and local anesthesia of the affected area. A 20 cc. sample of blood is drawn in a syringe utilizing an 18 gauge butterfly to prevent hemolysis. The syringe is preloaded with 1 cc. of sodium citrate as an anti-coagulant and the blood is introduced to the separation chamber using aseptic technique. The blood is separated and the platelets are concentrated in the 14 minute spin cycle. A 2/3 aliquot of platelet poor plasma is removed and the concentrated platelets are resuspended in the plasma. The PRP, 3 ml in volume, is drawn into a 10 cc syringe and an 18 gauge needle is applied. Ultrasound is used to detect the ruptured area of the tendon, and the needle is introduced percutaneously. Under direct supervision with the ultrasound, the PRP is injected into the tendinous defect after the sight has been tested for anesthesia. Proper placement of the graft is confirmed and a light bandage is applied with mild compression. Postoperative pain is controlled with acetaminophen and narcotic analgesics. NSAID's are not indicated postoperatively. The patient is monitored at weeks 1,2,4 and 6 with ultrasound and clinical examination.

## **CONCLUSION**

Platelets release a number of growth factors which are necessary for wound healing. Chronic tendon injury, like all soft tissue repair, requires these growth factors for healing. Two cases were carefully selected for APG with PRP and both resulted in successful tendon repair, both clinically and with ultrasound imaging. The use of PRP in soft tissue repair has been historically demonstrated to be effective in many surgical applications and this appears to be another viable use to enhance patient care. Because the graft is autologous, rejection is not a concern. Although additional studies with a broader patient base are needed to prove decreased postoperative healing times, less complications and increased efficacy of APG, these case studies show great promise for successful, minimally invasive tendon repair.

## **References**

1. Barrett, Stephen L., The Use of Autologous Platelet Concentrate Grafting in the treatment of Recalcitrant Wounds, Unpublished White Paper Monograph.
  2. Petrunaro, Paul S., The Use of Platelet Rich Plasma with Growth Factors to Enhance Hard and Soft Tissue Healing and Maturation in Surgical Implant Dentistry., Contemporary Periodontics & Implantology., Nov. 2000, 1(6) pp 1-4.
  3. Almekinders, Louis C., A Biologic Approach to the Treatment of Tendinopathy, Unpublished White Paper Monograph.
  4. Barrett, Stephen L., Growth Factors for Chronic Plantar Fasciitis?, Podiatry Today, Nov. 2004, pp 37-42.
  5. Aspenberg, Per, Platelet Concentrate Injection Improves Achilles Tendon Repair in Rats, Acta Orthop Scand., 2004, 75(1) pp 93-99.
  6. Edwards, Scott G., Autologous Blood Injections for Refractory Lateral Epicondylitis, Journal of Hand Surgery, March 2003, 28(2) pp 272-278.
  7. Tischler, Michael, PRP: The Use of Autologous Growth Factors to Enhance Bone and Soft Tissue Grafts, NYSDJ, March 2002, pp 22-24.
-